

From the Department of Breast and Endocrine Surgery  
Department of Reconstructive Plastic Surgery  
Karolinska University Hospital  
Department of Molecular Medicine and Surgery  
Karolinska Institutet, Stockholm, Sweden

# Primary reconstruction with implants in breast cancer

## Aspects of oncological safety and aesthetic outcome

Catharina Eriksen



Stockholm 2011-05-20

All previously published papers were reproduced with permission from the publisher.

Published by Karolinska Institutet  
Printed by Larseric Digital Print AB

Catharina Eriksen 2011  
[Catharina.eriksen@karolinska.se](mailto:Catharina.eriksen@karolinska.se)  
ISBN 978-91-7457-318-3

***“Du ska få en dag i måå  
som rein og ubrukt står”***

*(Alf Pröysen)*



## CONTENTS

---

<b>ABSTRACT</b> .....	1
<b>LIST OF ABBREVIATIONS</b> .....	2
<b>LIST OF PUBLICATIONS</b> .....	3
<b>INTRODUCTION</b> .....	5
<b>BACKGROUND</b> .....	7
<i>BREAST CANCER</i> .....	7
<i>Epidemiology</i> .....	7
<i>Etiology</i> .....	7
<i>Diagnosis</i> .....	7
<i>Treatment</i> .....	8
<i>Prognosis</i> .....	9
<i>Local recurrence</i> .....	10
<i>HISTORY OF BREAST CANCER SURGERY</i> .....	10
<i>HISTORY OF RECONSTRUCTIVE BREAST SURGERY</i> .....	11
<i>QUALITY OF LIFE</i> .....	14
<i>AESTHETIC EVALUATION</i> .....	14
<b>SPECIFIC AIMS OF THE THESIS</b> .....	17
<b>PATIENTS AND METHODS</b> .....	18
<i>Paper I</i> .....	19
<i>Paper II</i> .....	20
<i>Paper III</i> .....	20
<i>Paper IV</i> .....	21
<i>STATISTICAL METHODS</i> .....	21
<b>RESULTS</b> .....	23
<i>Paper I</i> .....	23
<i>Paper II</i> .....	25
<i>Paper III</i> .....	25
<i>Paper IV</i> .....	27
<b>DISCUSSION</b> .....	31
<i>Paper I</i> .....	31
<i>Paper II</i> .....	32
<i>Paper III</i> .....	33
<i>Paper IV</i> .....	34
<b>CONCLUSIONS</b> .....	37
<b>FUTURE PERSPECTIVES</b> .....	39
<b>SWEDISH SUMMARY</b> .....	41
<b>REFERENCES</b> .....	45
<b>ACKNOWLEDGEMENTS</b> .....	55



## ABSTRACT

---

*Introduction:* Despite the introduction of breast conserving surgery, in Sweden mastectomy is still annually recommended to 40–50 % (about 3000) of women with breast cancer. National guidelines state that, in the absence of contraindications, these women should be offered breast reconstruction. Immediate reconstruction has many advantages compared with delayed reconstruction but questions have been raised about the method's oncological safety and which method is preferable.

*Aim:* The first aim was to clarify whether it is sufficiently safe oncologically to offer breast cancer patients primary reconstruction with implants. The next aim was to evaluate different techniques for objective evaluation of breast volume and shape. The third and final aim was to compare two different expander implants regarding the number of operations needed to achieve patient satisfaction, and to measure and compare their cosmetic outcomes objectively and subjectively.

*Patients and methods:* In a long-term follow-up (median 11.5 years) cohort study, 300 representative invasive breast cancer patients operated with primary reconstruction with implants were compared to 300 matched controls operated with mastectomy alone (*Paper I*). In a pilot study, 25 patients were operated with a new crescent-shaped expander implant and the result was compared with those seen after surgery with traditional expander implants (*Paper II*). Twelve patients were included, 6 preoperatively and 6 postoperatively, in a methodological analysis comparing five different methods for evaluating the volume and shape of the breast (*Paper III*). The final study (*Paper IV*) was a prospective trial evaluating 40 patients, randomised to either a round one-stage permanent expander implant (n=20) or a crescent two-stage implant procedure (n=20). The number of operations needed and the patients' satisfaction were evaluated and compared by two panels, one of experts and one of lay people. Objective measurement methods for evaluation of volume and contour differences between the breasts were tested. Quality of life was evaluated with the SF-36 health declaration.

*Results:* There were no significant differences between mastectomy with and without primary reconstruction regarding incidence of local and/or regional recurrences, or time to start of oncological treatment (*Paper I*). The outcome with the crescent-shaped expander gave an impression of a more naturally shaped breast (*Paper II*), which was confirmed in the randomized study. Of the patients operated with the one-stage procedure, 70 % had revision surgery. No major differences were seen between the groups regarding quality of life (*Paper IV*). Volume was estimated significantly better with traditional, simpler methods like plastic casts compared to modern technology like Magnetic Resonance Imaging and three-dimensional techniques, which tended to overestimate volume. Shape could be measured objectively with a two-dimensional technique based on three-dimensional laser scanning (*Paper III*).

*Conclusion:* The cohort study with a well-matched control group demonstrates that immediate breast reconstruction with implants can be offered and performed on patients with invasive breast cancer without any negative effect on oncological safety. The two-stage crescent method gave better aesthetic results than the one-stage procedure, which in a majority of the patients failed to be a one-stage method. An easy and simple method like plastic casts gave more accurate measurements of breast volume than advanced techniques. Laser scanning is a new method for objective measurement of shape and symmetry.

## LIST OF ABBREVIATIONS

---

BCS	Breast conserving surgery
BMI	Body mass index
BP	Bodily pain
BRCA1	Breast cancer susceptibility gene 1
BRCA2	Breast cancer susceptibility gene 2
CT	Computer tomography
DCIS	Ductal carcinoma in situ
CMF	Cyclophosphamid, 5-fluorouracil and methotrexate
DIEP	Deep inferior epigastric perforators flap
DFS	Disease free survival
DM	Distant metastasis
ER	Estrogen receptor
FEC	5-Floururacil, epirubicin and cyclophosphamid
GH	General health
HRT	Hormone replacement therapy
HRQOL	Health related quality of life
IBR	Immediate breast reconstruction
ICC	Intraclass correlation coefficient
KTH	Kungliga tekniska högskolan (Royal institut of technology)
LABC	Local advanced breast cancer
LD	Latissimus dorsi
LR	Local recurrence
MH	Mental health
MRI	Magnetic resonance imaging
NAC	Nipple areola complex
OC	Oncological centre
OS	Overall survival
PF	Physical functioning
RE	Emotional role functioning
RP	Physical role functioning
PR	Progesterone receptor
PRO	Patient reported outcome
RR	Regional recurrence
SF	Social functioning
SF-36	Medical outcome study 36-item short form
SIEA	Superficial inferior epigastric artery
SN	Sentinel node
3-D	Three-dimensional
TMG	Transverse musculocutaneous gracilis flap
TNM	Tumour node metastasis
TRAM	Transverse rectus abdominis myocutaneous flap
VT	Vitality



## LIST OF PUBLICATIONS

---

This thesis is based on the following papers, which are referred to in the text by the Roman numerals given below (I–IV):

- I. **Eriksen C**, Frisell J, Wickman M, Lidbrink E, Krawiec K, Sandelin K  
Immediate reconstruction with implants in women with invasive breast cancer does not affect oncological safety in a matched cohort study.  
*Published on line: Breast Cancer Research and Treatment March 15- 2011*
- II. **Eriksen C**, Stark B  
Early experience with the crescent expander in immediate and delayed breast reconstruction.  
*Scand J Plast and Reconstr Surg and Hand Surg 2006; 40:82-88*
- III. **Eriksen C**, Nordstrand Lindgren E, Olivecrona H, Frisell J, Stark B  
Evaluation of volume and shape of breasts: Comparison between traditional and three-dimensional techniques.  
*Journal of Plastic and Reconstructive Surgery and Hand Surgery 2011; 45:14-22*
- IV. **Eriksen C**, Nordstrand Lindgren E, Frisell J, Stark B  
A prospective randomised study comparing two different expander implants in primary reconstructions for breast cancer.  
*In manuscript.*



## INTRODUCTION

---

Survival in breast cancer is high and today there are about 80,000 women living in Sweden who have a history of breast cancer [1, 2]. However, despite the availability of breast conserving surgery (BCS), removal of the entire breast is still performed in about 40–50% of breast cancer patients and many women fear the surgical trauma and feeling of being mutilated by a mastectomy [3]. The loss of a breast is a psychological and physical traumatic event and influences the quality of life and body image for many women in all ages [4-10]. There is a growing demand for breast reconstruction and we now have the technique and the possibility to offer breast cancer patients this option in the absence of contraindications. The choice between primary and delayed reconstruction has to be made. Immediate breast reconstruction (IBR) has advantages over delayed reconstruction but questions have been raised about oncological safety [11-13].

The main intention in breast reconstruction must be to individualize each reconstructive method to meet patients' expectations and wishes, always taking oncological aspects into consideration. Traditionally, women with ductal cancer in situ (DCIS) and T1-2 tumours are offered IBR, while those with presumptive radiotherapy or local advanced breast cancer (LABC) are recommended delayed procedures [14-16]. The general opinion has been that delayed reconstruction should be performed not earlier than two years after adjuvant treatment, i.e. after the period with the highest risk of recurrence.

Although several studies indicate that IBR is oncologically safe, many patients and physicians are still uncertain about this method [17-32]. There has been a concern that, due to more extensive surgery with a higher risk of postoperative complications, IBR may delay the oncological treatment. The first aim of this thesis was to evaluate the oncological safety of IBR with implants.

Notwithstanding the development of advanced techniques with microsurgical flap surgery, the majority of women offered IBR still undergo reconstruction with implants [33]. Traditional breast expander implants, round as well as anatomically shaped, have known

drawbacks, such as undesirable fullness of the upper pole and inadequate expansion of the lower pole, often leading to poor ptosis of the reconstructed breast [34, 35].

The next aim of the thesis was to evaluate traditional methods with new 2- and 3-D techniques for objective measurement and evaluation of breast volume and shape.

A crescent-shaped expander especially expanding the lower pole of the breast may be capable of producing a more natural shape [36]. The final aim of the thesis was to evaluate the crescent expander implant and compare its outcome with that of traditional expander implants.

## BACKGROUND

---

### ***Breast cancer***

#### *Epidemiology*

The incidence of breast cancer varies internationally but in western countries this is the most common female cancer [37, 38]. In Sweden, more than 7000 women are diagnosed with breast cancer annually, which is equivalent to 30% of all female malignancies (Figure 1) [1, 39]. The mean age at diagnosis is 63 years; 18% are younger than 50 years and 4.5% younger than 40 (Figure 2). After rising 1.4% annually in the past few decades, the annual incidence of breast cancer in Sweden has stabilized or even decreased in recent years [1, 39]. However, in many newly industrialized countries the incidence is increasing rapidly with changing lifestyles, indicating environmental changes as important risk factors [1, 40].

#### *Etiology*

The etiology of breast cancer is multi-factorial and still not fully known. Hereditary breast cancer is considered to be present in less than 10% of the patients, and of those a mutation in Breast Cancer susceptibility gene (BRCA) 1 or 2 is the cause in 1/3 of the cases [41, 42]. Other risk factors that can influence the development of breast cancer are obesity, alcohol habits, smoking, low parity, late and low childbirth, early menarche, late menopause, hormone replacement therapy and amount of breast tissue [1].

#### *Diagnosis*

Today, breast cancer diagnosis is based on a triple diagnostic procedure with clinical examination of the breast, (radiological) mammography/ultrasound and fine-needle aspiration/core biopsy. The sensitivity of this triple procedure is very high, with less than 1% missed cases [43]. Complimentary methods such as magnetic resonance imaging (MRI) can be used.

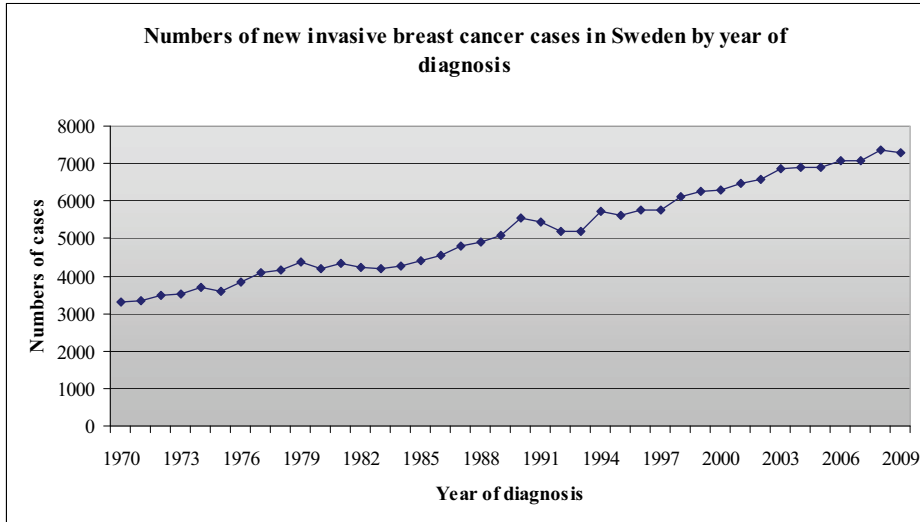


Figure 1

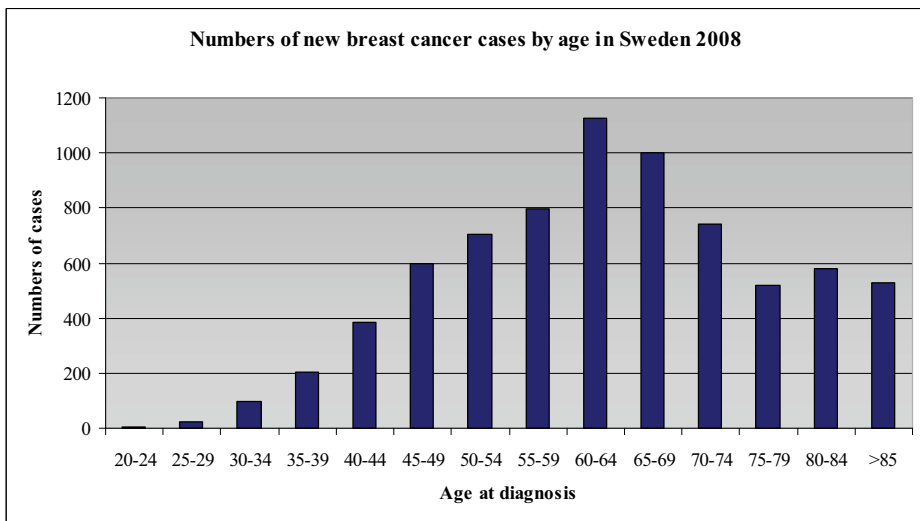


Figure 2.

Source Figure 1-2: [www.socialstyrelsen.se/statistik/statistikdatabas](http://www.socialstyrelsen.se/statistik/statistikdatabas)

### *Treatment*

Sweden has national guidelines for the treatment of breast cancer. Today, primary treatment in most patients is surgery with additional adjuvant therapy, such as chemotherapy, endocrine therapy, radiotherapy and target drugs, administered as single

therapy or in various combinations [1]. About 60% of the patients are operated with BCS with removal of only the tumour-bearing part of the breast. After BCS, radiotherapy is always recommended in order to reduce the risk of local recurrence and to improve survival [44]. In patients with large tumours, multicentric or inflammatory cancer, mastectomy is recommended. Patients with advanced tumour stage are offered neoadjuvant therapy before surgery [1, 45]. In invasive breast cancer surgery, the operation is always accompanied by a staging procedure in the axilla. Axillary clearance with removal of 10–15 lymph nodes has been replaced by sentinel node (SN) biopsy in node negative patients. SN is the first node in the axilla that drains the breast tumour. Perioperative pathological examination of the SN spares 60–70 % of all breast cancer patients from major surgery in the axilla [46-48].

### *Prognosis*

Mortality has been relatively stable or slowly decreasing, with approximately 1500 breast cancer deaths per year in Sweden (Figure 3) [1, 39]. The improved prognosis may be due to a combination of early detection by screening mammography, increased awareness and better treatment [1].

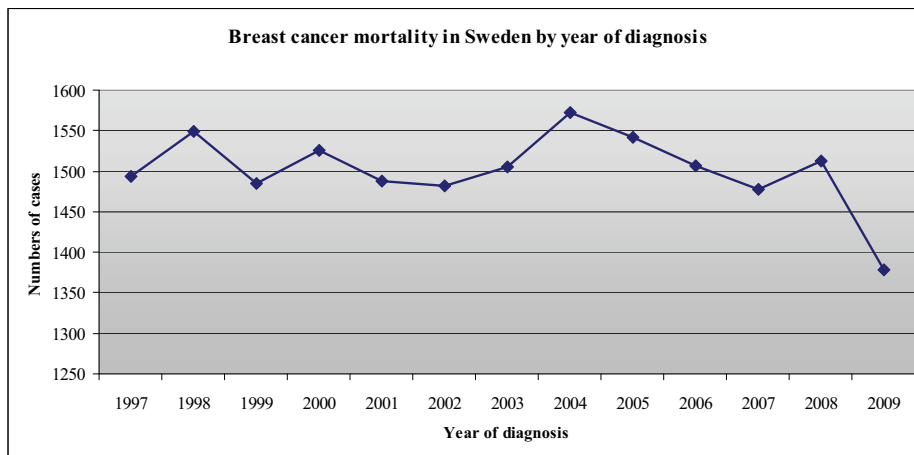


Figure 3.

Source: [www.socialstyrelsen.se/statistik/statistikdatabas](http://www.socialstyrelsen.se/statistik/statistikdatabas)

The main prognostic factors are the patient's age and the tumour stage according to the TNM classification, which is based on the size of the primary tumour (T), and the presence of regional lymph node metastases (N) and distant metastases (M) [1, 39, 49]. A retrospective American study, published in 1998, gave the following 10-year survival rates: Stage 0 patients 95%, Stage 1 patients 88%, Stage 2 patients 66%, Stage 3 patients 36% and Stage 4 patients 7% [50]. In Sweden the overall 5-year survival rate in 2007 was 87.8 % [1, 39].

#### *Local recurrence*

Local recurrence (LR) is usually defined as a recurrence of tumour growth in the skin, subcutaneous layer or chest wall in the area of the previous mastectomy or in the remaining breast after BCS. Quality criteria require that LR after breast conserving surgery for invasive cancer should not exceed 15% after 10 years and be less than 10% after mastectomy [51, 52]. More skin-sparing mastectomies do not seem to affect the LR rate [32, 53, 54].

#### ***History of breast cancer surgery***

More than 3500 years ago the ancient Egyptians described breast cancer as an untreatable disease, though attempts at treatment are documented in the Edwin Smith Papyrus [55]. Hippocrates (c.460–377 BC) described breast cancer as a humoural disease, in keeping with his division of the body fluids. He noted that an untreated tumour was black and hard in appearance and eventually penetrated the skin in the form of a black liquid. He also coined the word cancer from *karkinos*, the Greek word for crab. He considered that surgical treatment was considered inappropriate since survival was longer for those who did not undergo surgery [56]. Galen (129–c. 200 AD) also defined breast cancer as a systemic disease; treatment was strictly pharmacological and surgery was considered dangerous [57].

Until the 18th century it was widely accepted that Galen had the last word on breast cancer's causes and treatments. During the 18th and 19th centuries, a radical period, the humoural theory fell into disrepute and surgery was discussed and reviewed by numerous physicians, such as Hunter, Le Cat and others who sometimes used slightly unorthodox



methods to convince colleagues [58]. A variety of contemporary theories, some more trustworthy than others, linked breast cancer to sexual activity, the harmful effect of coagulated milk and mammary veins constricted by depression. However, unlike their ancient predecessors, the majority agreed that breast cancer was a local disease curable by surgery alone [58]. The advent of anaesthesia, blood transfusion and antimicrobial techniques made radical mastectomy possible. The foremost pioneer in this field was the American surgeon William Halsted (1852–1922), who developed radical mastectomy [59].

In the mid-1900s Bernard Fisher revolutionized cancer treatment with the theory of metastasis. As Hippocrates had hypothesised more than 2000 years earlier, he argued that breast cancer is a systemic disease in which cancer cells are transported within blood and lymphatic fluid, why surgical treatment alone is not sufficient. In 1976, Fisher started a randomised study which showed that BCS in conjunction with radiotherapy was as effective as radical mastectomy alone [60]. The modern approach to breast cancer surgery was born and further developed with the SN biopsy technique [46, 61-64].

Great progress was also being made in oncological treatment such as chemotherapy, radiotherapy, and endocrine therapy; together with the surgical developments, this lay the foundation for the golden standard for breast cancer treatment in the 1980–90s [1].

### ***History of reconstructive breast surgery***

Radical mastectomy extended life but was a mixed blessing. Patients became disfigured and often had chronic pain. Dr. Halsted considered these side effects “*a necessary evil and since the average age was nearly fifty-five years, they were no longer active members of society*” [59]. Fortunately, this attitude has changed, leading to the development of reconstructive breast cancer surgery and a focus on quality of life [65].

Historically, the first reconstruction, when V Czerny transferred a lipoma to the breast, was published in 1895 [66]. The first silicone implant was launched by Cronin and Gerow in 1961 and Arion introduced the first saline expander in 1964 [67, 68]. In 1984, Becker further developed the tissue expander, which came into frequent use in the 1990s and served as a permanent implant [69]. Since then, five generations of implants have been developed, with different covers, contents, sizes and shapes.

The most common types of implant used for reconstruction today are textured, anatomically-shaped silicone shells, filled with silicone, saline or a combination of the two (Figure 4) [70].

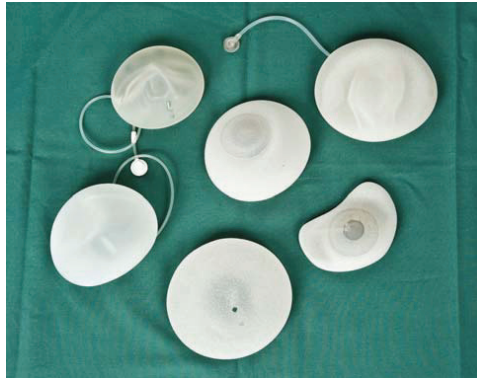

Figure 4. Different models of breast implants.

The development of implant-based reconstructions has been accompanied by the introduction of several autologous methods. An autologous technique involves transferring tissue to the site of the removed breast, either as a pedicled flap or with microsurgical technique as a free flap. The most common donor sites are the abdomen, the back or the gluteal region. In general, autologous breast reconstruction is more demanding than implant-based reconstruction resulting in larger incisions, more scars, longer operating time and more complications. On the other hand, in the longer run the aesthetic result may be better for some patients [71, 72].

A commonly used reconstructive technique is the latissimus dorsi (LD) flap, popularized in the 1970s [73-75]. The flap is tunneled under the skin to the mastectomy site as a pedicled flap, sometimes combined with an implant to obtain the desired volume. The LD flap can also be used alone as an extended flap, with fatty tissue harvested together with the muscle [76]. The lateral thoracodorsal flap, also known as the “Göteborg” flap, is a fasciocutaneous flap added from the lateral-dorsal thoracic wall to form the lateral part of the breast. This technique is also frequently combined with implants [77].

The transverse rectus abdominis myocutaneous flap (TRAM) was introduced for breast reconstruction in the 1980s; it can be either pedicled or used as a free flap [78, 79, 80]. Today, the free TRAM is often replaced by perforator flaps, such as the deep inferior epigastric perforator (DIEP) flap or the superficial inferior epigastric artery (SIEA) flap [81-84]. With these flaps, the muscle and fascia do not have to be removed from the abdomen. Only the skin, the subcutaneous tissue and the vessels are transferred, which has proved to be advantageous for the patients in terms of decreased donor-site morbidity and quicker recovery [85]. Alternatives are the free gluteal flap [86], the free anterolateral thigh flap [87] and the free transverse musculocutaneous gracilis (TMG) flap [88].

Ongoing development of new techniques, such as acellular dermal matrix for use in the lower pole of implant reconstructions, and refinement of older methods, such as lipofilling, creates new possibilities in the area of reconstructive breast surgery [76, 89, 90].

The choice of a reconstructive method is a multifactorial issue. Primary versus delayed? Implants versus autologous tissue, or a combination? Oncological considerations, local traditions, the patient's condition and preferences will influence the decision. Local access to professional competence for reconstruction may also affect the choice between IBR and a delayed procedure. Breast reconstructions were first performed as a delayed procedure by plastic surgeons. The number of IBR has increased in recent years and so has the number of breast surgeons performing reconstructive oncoplastic breast surgery. Cooperation between breast and plastic surgeons at major breast centres has made IBR more accessible. However, the proportion of breast cancer patients who undergo IBR in Sweden is only 6 % [91].

### ***Quality of life***

The concept of health-related quality of life (HRQOL) comprises a wide range of aspects with a variety of definitions, mostly focusing on physical functioning, mental health, social, emotional and sexual wellbeing in relation to a medical condition and treatment [92, 93].

Breast cancer survivors is a growing group of women who desire excellent treatment and a good quality of life. The breast is involved in many women's expectations regard to body image, breastfeeding and sexual aspects, for instance. The feeling of being mutilated and unattractive is still a big issue for many women, especially those facing mastectomy. The aim of breast reconstruction is to improve these patients' HRQOL [94-97].

Breast cancer surgery does affect women's body image and many questionnaires have been developed for patient-reported outcomes (PRO). Only a few have been validated and specifically address breast cancer surgery with the ability to measure the individual patient's outcome. The choice of surgical procedure to recommend with reference to HRQOL is a difficult decision [93, 98].

One must not forget that whichever method is chosen for breast reconstruction, the procedure inevitably involves more physical trauma than mastectomy alone. A fair number of women choose not to have a breast reconstruction which can be an excellent choice for a high quality of life, depending on the patient's preferences [99].

### ***Aesthetic evaluation***

An objective method for evaluation makes it possible to set standards and thereby compare and evaluate the aesthetic results of different surgical techniques. Many attempts have been made to objectively evaluate breast shape, volume and contour, both before and after surgery. These evaluations involve volume measurement by MRI, computed tomography (CT), mammography, water displacement, plastic cups or thermoplastic casts and assessment of shape and symmetry by anatomical measurement and three-dimensional (3-D) techniques (Figure 5) [100-108]. There is now a wide variety of reconstructive methods and a constant development, which makes objective evaluation for comparison of results even more important. The results of breast reconstruction can be evaluated objectively and

subjectively. Subjective evaluation comprises the patient's satisfaction or a jury's assessment of patient images; this can be a problem since the results are based on people's opinions in accordance with their expectations. A patient may be very unsatisfied with a result that is "perfect" from a surgeon's point of view. On the other hand, a surgeon may find a result poor even when the patient is very satisfied (Figure 6, 7 a-c).



Figure 5. Postoperative 3-D laser scan imaging.

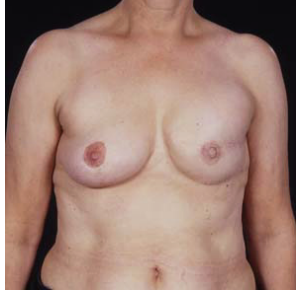

Figure 6 (a)

Figure 6. Result after IBR with an anatomical expander on the left side and a mastopexy on the right side. This patient was very satisfied with the result despite of the upper pole fullness seen in figure 6 b.

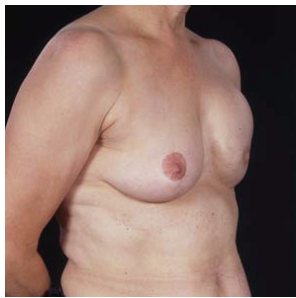

Figure 6 (b)

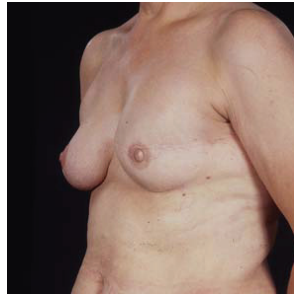

Figure 6 (c)

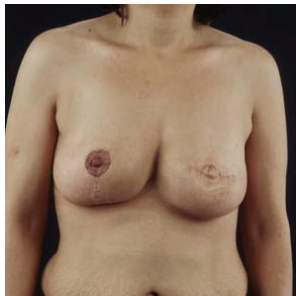


Figure 7 (a)

Figure 7. Postoperative result after a two stage reconstruction on the left side and a breast reduction on the right side. This patient was very dissatisfied while the surgeon rated the result as very good.

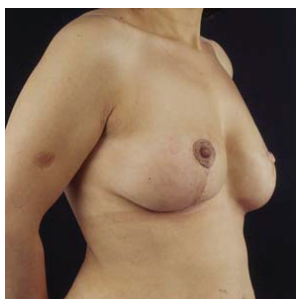

Figure 7 (b)

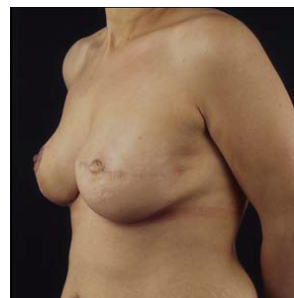

Figure 7 (c)

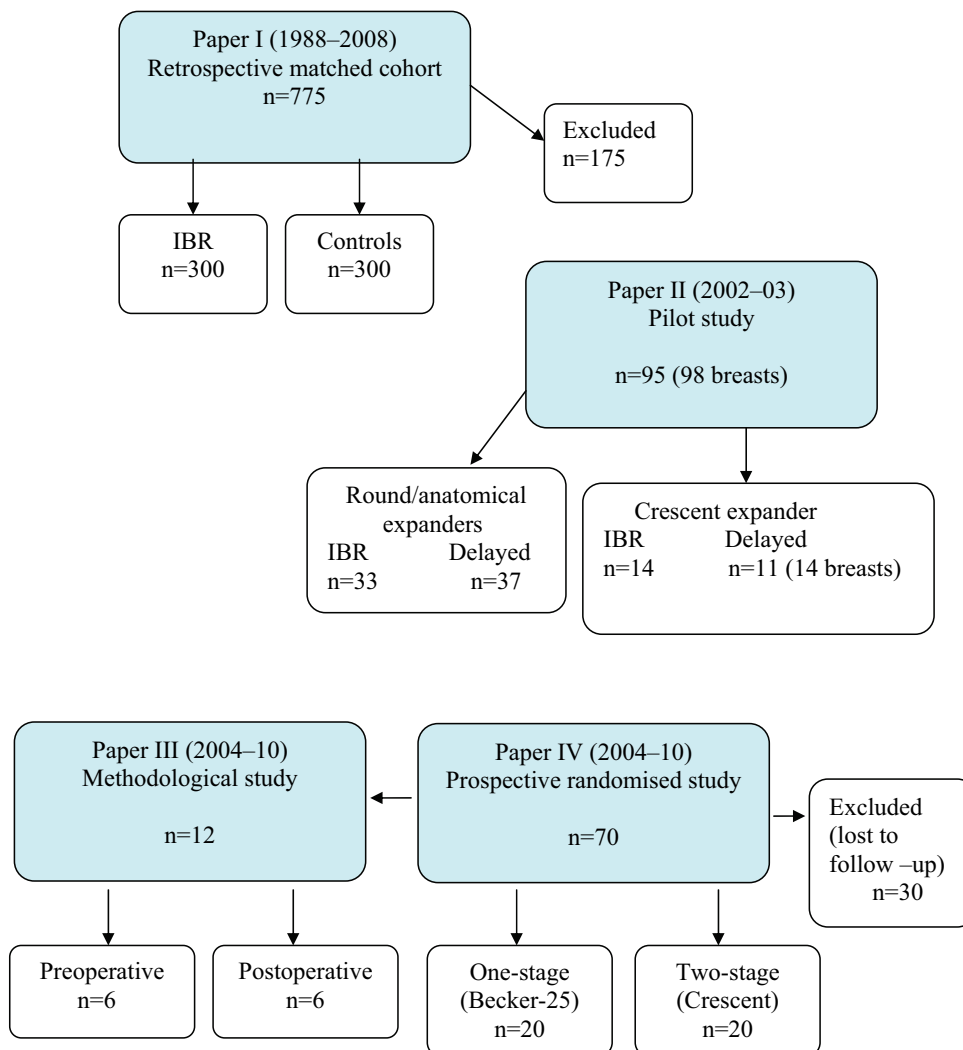
## SPECIFIC AIMS OF THE THESIS

---

- To analyse long-term results of IBR with implants with regard to local, regional and distant recurrences and survival compared to women operated with mastectomy alone. To study whether IBR affects time to postoperative adjuvant treatment.
- To evaluate a consecutive group of patients having immediate or delayed breast reconstruction with a new crescent-shaped expander and to compare the results with patients operated with round or anatomically-shaped expander implants.
- To define the most reliable method for objective evaluation of breast volume and shape, pre- and postoperatively, in breast cancer patients undergoing primary breast reconstruction with implants.
- To evaluate the crescent-shaped two-stage expander method with a traditional permanent round expander implant and to compare this, using objective measurements, including 3-D laser scanner, with subjective evaluation of the aesthetic outcome.

## PATIENTS AND METHODS

Flow chart of patients included in the thesis





### *Paper I*

In a retrospective cohort study, 475 consecutive patients with primary breast cancer were operated with IBR with implants. The patients had been registered prospectively in a separate database and only those with invasive breast cancer with a follow-up of at least 4 years were included (n=300). This cohort of patients was matched with women from the Regional Breast Cancer Register of Stockholm-Gotland who had been operated with mastectomy without IBR. Each case in the IBR group was matched with one control in terms of age, tumour size, nodal status and year of operation, with a median follow-up of 11.5 years.

All patients were discussed pre- and postoperatively at the multidisciplinary team conference. Patients with inflammatory breast cancer or tumours adhering to the pectoral muscle or skin were not offered IBR, neither were women with high body mass index (BMI) or heavy smokers, as they were considered to be unsuitable for implant reconstruction. Patients with large tumours, neo-adjuvant chemotherapy and planned for postoperative radiotherapy were included, while those reconstructed after earlier ipsilateral breast cancer were classified as LR and excluded from the study.

Mastectomy was performed with earlier scars (if BCS was not radical) and the nipple-areola complex (NAC) excised and with the inner blade of the pectoral fascia left intact. The SN biopsy technique was introduced in 1998 and gradually replaced axillary clearance in node negative patients. All women in the IBR group were operated with permanent or expandable implants placed submuscularly to achieve full muscle cover.

Oncological treatment was based on recommendations and guidelines from the Stockholm Cancer Study Group.

The patients were followed for a total of 5 years at the Oncological Department. Patients with no sign of recurrences were then referred to the general practitioners for further follow-up. The patients in the IBR group were followed separately at the Department of Reconstructive Surgery for evaluation and further assessments.

Variables from clinical records were registered and patients were followed until the end of June 2008. Type of breast cancer, Elston grade [109, 110], hormonal status, time to oncological treatment, type of chemotherapy, radiotherapy and early complications were

registered, as were incidence of recurrences, time to detection, how the recurrences were detected and survival. The results were compared with data from the Oncologic Centre (OC) in Stockholm and from the National Cause of Death Register.

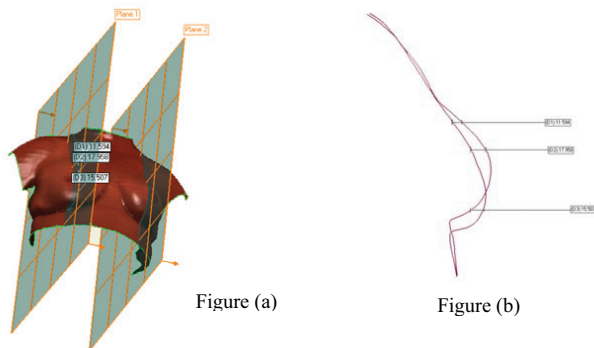
*Paper II*

In a pilot study, 25 breast cancer patients were operated with a new crescent-shaped expander implant; bilateral reconstruction was performed in three of them. Further, medical records were reviewed in 70 patients operated with round or anatomically shaped expander implants. The crescent expander has a magnetic filling port incorporated in the centre of the implant, while the traditional expander has a separate filling port placed subcutaneously. Forty-seven patients were operated with IBR and 48 patients had delayed procedures. Nine (36 %) of the patients operated with the crescent-shaped expander received radiotherapy compared to 12 (17 %) patients in the other group. Data concerning adjuvant treatment, complication rate, fullness of the upper pole, the necessity of revision, and the patient's satisfaction were recorded.

*Paper III*

From the prospective randomised trial (*paper IV*) evaluating two different implants in IBR, 12 patients were selected for this study and divided into two groups. Breast volume and shape were evaluated in six patients preoperatively and in another six postoperatively. Breast volume was measured in the preoperative group using standardized plastic cups, thermoplastic cast material, MRI and 3-D laser scanner. Contour/shape was evaluated with a two-dimensional technique based on 3-D laser scan imaging (Figure 8 a, b). The same procedures were used for patients in the postoperative group and in addition, volume was assessed with another 3-D analysis based on stereophotographic images. The mastectomy specimen was measured by fluid displacement in ml (Archimedes' principle) and by weight in grams and served as a control for the volume measurements. For evaluation of shape, the opposite healthy breast served as a reference.

Figure 8. (a) Sagittal sections in 3-D laser scan imaging.  
(b) Contour differences between the breasts.



#### *Paper IV*

In order to compare two different expander implants, a prospective randomised study was designed. Power estimation was based on experience from paper II and 40 patients were needed. Breast cancer patients scheduled for IBR with implants were eligible for participation. Seventy patients were included in the study, 40 patients (20 in each group) were evaluated, while 30 patients were lost to follow-up. Patients were randomised to either a one-stage round permanent expander (Becker 25) featuring a separate filling port, or a two-stage crescent-shaped expander (McGhan 133 LV) with an integrated magnetic filling port, replaced in a second stage by an anatomical silicon implant.

Preoperatively, jugulum-nipple distance and ptosis (cm) were recorded. Breast base width was measured with a rigid measurement device. Breast volume was measured using standardised plastic cups and thermoplastic sheet material (Orfit); photographic images were obtained.

All patients were operated by a standard mastectomy. The mastectomy specimen was measured by Archimedes' principle in millilitres and by weight in grams. The number of operations, additional revision surgery and complications in the two groups were documented. Postoperatively, the patients were measured in the same way as preoperatively and additionally by a 3-D laser scanner and two-dimensional evaluation of contour differences between the breasts. The patient's satisfaction regarding shape, volume and symmetry was recorded on a scale from 1–6 (1=very bad, 6=very good). Two panels, one of experts and one of lay people, evaluated the aesthetic results on the same scale and their assessments were compared with the patient's satisfaction. Postoperatively, the expert panel also evaluated indication for further revision surgery in the one-stage group. Quality of life was evaluated with SF-36 (Short Form medical outcome) a validated health declaration; 36-item, before and after surgery.

#### ***Statistical methods***

*Paper I:* The McNemar test and the Stuart-Maxwell test were used for pairwise comparison of categorical variables. When pairwise comparison was not appropriate, Person's chi-square test for categorical variables and the Mann-Whitney-Wilcoxon test for continuous

variables were performed. The Kaplan-Meier method was used to calculate disease-free survival as well as breast cancer specific survival. Hazard ratios and 95 % confidence intervals were estimated with the Cox proportional hazard regression model with stratification on the matched pairs. All statistical analyses were performed in STATA/IC statistical software, version 10.0.

*Paper III:* Paired *t*-test and repeated ANOVA were used to evaluate whether there were significant differences between the methods. Pairwise comparisons were made, and the Bonferroni correction applied. The validation of the MRI and the three-dimensional methods was tested by intraclass correlation coefficient (ICC).

*Paper IV:* Before the study, a power analysis indicated that a total of 40 patients was needed, with 20 in each group, based on a one-sided test  $\alpha=0.05$  and a power  $1-\beta=0.90$ ,  $\pi_1=0.25$  and  $\pi_2=0.70$ . Fisher's exact test was used for calculation of significance, comparing the revision rate in the one-stage and two-stage groups. Tests were significant at  $p < 0.0500$ . Variables were summarized using standard descriptive statistics such as frequencies, means, medians and standard deviations. Sign-tests were applied for comparison of patient-based data before and after revision surgery in the one-stage group. Mann-Whitney U-tests were applied for evaluation of patients' final scores between the two groups. The kappa-statistic measure of agreement was used to analyse the agreement in the indication for revision surgery in the expert group (0.0=poor, 0.81–1.00=almost perfect). Paired and unpaired *t*-tests were used to analyse differences between the groups in the SF-36 health declaration.

## RESULTS

### *Paper I*

The two groups were well matched and comparable, with small differences. The median tumour size was 19 and 20 mm; node positive disease was present in 36% and 36.7%; further clinical and histopathological characteristics are presented in (Table I).

	IBR n = 300	Controls n = 300	p-value
<b>Age</b>			
Median, years	48	48	
Range, years	23-70	28-69	
<b>Tumor size (mm)</b>			
Median	19	20	
Range	0-100	0-90	
<b>Lymph nodes (%)</b>			
0	64.0	63.3	
1-3	23.0	22.0	
≥4	13.0	14.7	
<b>Morphology (%)</b>	n = 291	n = 283	
Ductal	66.3	79.9	0.003 <sup>1</sup>
Lobular	27.2	16.2	
Other	6.5	3.9	
<b>Hormone receptor status (%)</b>	n = 274	n = 287	
ER +	79.9	68.6	0.003 <sup>2</sup>
	n = 251	n = 275	
PR +	71.3	61.1	0.008 <sup>2</sup>

Table I. Patients' clinical and histopathological characteristics. Immediate breast reconstruction (IBR), estrogen receptor (ER), progesterone receptor (PR),  
(<sup>1</sup>Stuart-Maxwell test, <sup>2</sup>McNemar chi-square test).

Lobular cancers and hormone receptor-positive tumours were more prevalent in the IBR group and the patients in this group more often received endocrine treatment. There were no significant differences between the two groups in the proportion of patients treated with neoadjuvant chemotherapy, in those receiving adjuvant chemotherapy or in those receiving postoperative radiotherapy. Furthermore, no differences were seen between the two groups in early postoperative complication rates or in time to initiate oncological treatment (Table II).

	IBR n = 300	Controls n = 300	p-value <sup>1</sup>
<b>Neoadjuvant chemotherapy (%)</b>	13.0	15.7	0.346
<b>Adjuvant chemotherapy (%)</b>	n = 292	n = 290	
	45.2	47.6	0.431
<b>Completed chemotherapy (%)</b>	n = 122	n = 119	
	94.3	92.4	0.569 <sup>2</sup>
<b>Time to chemotherapy (weeks)</b>	n = 112	n = 105	
Median	5.0	5.1	0.376 <sup>2</sup>
Range	2-22	2-33	
<b>Hormonal treatment (%)</b>	n = 283	n = 273	
	73.8	66.3	0.103
<b>Radiotherapy (%)</b>	n = 289	n = 284	
	34.2	32.8	0.825
<b>Time to radiotherapy (weeks)</b>	n = 86	n = 70	
Median	24.1	24.7	0.902 <sup>2</sup>
Range	6-48	5-42	
<b>Complications &lt; 30 days (%)</b>	7.3	6.3	0.622

Table II. Oncological treatment, time to treatment and complications. Immediate breast reconstruction (IBR), (<sup>1</sup> McNemar chi-square test unless otherwise stated, <sup>2</sup> Person's chi-square test for categorical variables; Mann-Whitney-Wilcoxon test for continuous variables).

In the analysis of first events, the incidence of all recurrences was 28.4% in the IBR group and 32.8 % in the control group. There were no significant differences in either local recurrences in the breast (8.2% in the IBR group, 9.0% in the control group) or in the regional recurrence rate (8.2% and 9.7%, respectively), while distant metastases were significantly more frequent in the control group (20.3% and 27.1%, respectively), p=0.049. The mean time to detection of local recurrence was 1.3 years in the IBR group versus 2.2 years in the control group (Table III). The majority of local recurrences were detected by clinical examination (94%); there were no significant differences between the two groups in the detection of either regional recurrences or distant metastases. The IBR group had a longer survival time; the differences in breast cancer mortality and all-causes mortality were statistically significant.

	Total number of events			First event		
	IBR	Controls	p-value <sup>1</sup>	IBR	Controls	p-value <sup>1</sup>
<b>Overall recurrence (%)</b>	28.4	32.8	0.239			
<b>Local recurrence (%)</b>	8.2	9.0	0.879	6.9	6.4	0.590
Time to detection (years)						
Median	1.3	2.2	0.763 <sup>2</sup>	1.3	1.6	0.673 <sup>2</sup>
Range	0.2-11.9	0.5-11.6		0.2-11.9	0.5-11.6	
<b>Regional recurrence (%)</b>	8.2	9.7	0.555	6.5	6.4	1.000
Time to detection (year)						
Median	4.8	1.6	0.008 <sup>2</sup>	2.6	1.5	0.014 <sup>2</sup>
Range	0.1-12.5	0.3-11.0		0.1-11.5	0.3-5.5	
<b>Distant metastases (%)</b>	20.3	27.1	0.049	14.8	20.1	0.081
Time to detection (year)						
Median	2.7	3.3	0.372 <sup>2</sup>	2.3	3.3	0.288 <sup>2</sup>
Range	0.0-12.4	0.0-13.9		0.0-12.4	0.0-13.9	

Table III. Incidence, detection mode and time to detection of recurrence. Immediate breast reconstruction (IBR). <sup>1</sup>McNemar chi-square unless otherwise stated, (<sup>2</sup>Person's chi-square test for categorical variables; Mann-Whitney-Wilcoxon test for continuous variables).

### *Paper II*

Of the 70 patients operated on with round or anatomically shaped expanders, 61 (87%) were dissatisfied with the aesthetic result. The main reason for this was asymmetry of form caused by fullness of the upper pole of the reconstructed breast. The patient's dissatisfaction led to reoperation with an anatomically-shaped permanent implant in 74% (52/70). Patients operated with the crescent-shaped expander were followed for a mean of 8 (4–15) months; replacement of the crescent expander with a form-stable anatomical implant was performed 6–8 months after the primary operation. Of the 25 patients operated with the crescent procedure, four developed complications. In 23 reconstructions the aesthetic result with the crescent-shaped expander was rated as good/very good by the patients.

### *Paper III*

The peroperative volume of the resected breast measured according to the Archimedes principal correlated well with its weight ( $p=0.64$ ) and was defined as the true volume of the breast. Statistically significant differences were detected when MRI, 3-D and plastic cups were compared with the Archimedes method. In contrast, no significant difference was detected between plastic casts (Orfit) ( $p=0.17$ ) and the Archimedes method.

Validations of the volume calculations with the MRI and 3-D methods also showed high correlations between the observers in terms of ICC.

For the postoperative group, the correlations between the results from five different measuring methods are shown in Figure 9. As with the preoperative group, the MRI and 3-D techniques showed statistically significantly larger volumes than the traditional methods. Individual differences between the breasts was not detected ( $p=0.63$ ).

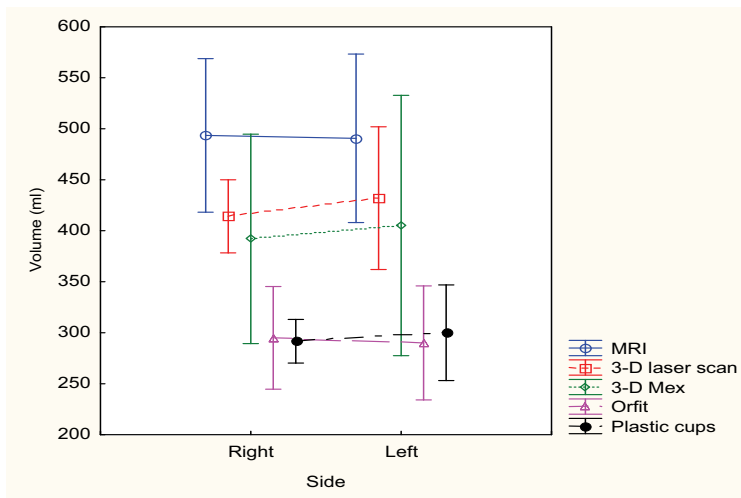


Figure 9. The correlation between five different methods of volume measurement

The differences in contour showed larger discrepancies between the breasts in postoperative patients than in the unoperated women in the preoperative group (Figure 10).

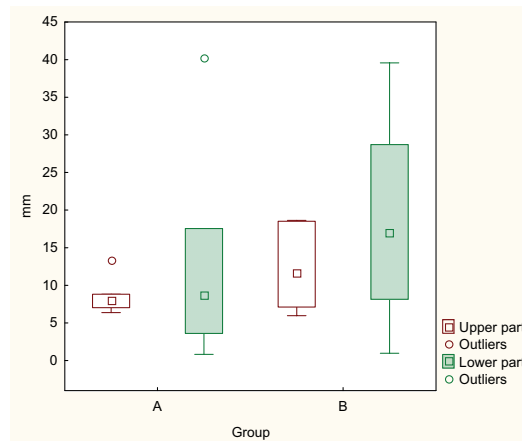


Figure 10. The differences in contour between the breasts expressed in mm, A= preoperative and B=postoperative group.



#### *Paper IV*

Forty women (20 in each group), out of the 70 included, completed the study and were followed for a median of 3.5 (range 1.5–5) years after the primary operation. The mean time for completing the reconstruction was 18.8 months in the one-stage group and 20.5 months in the two-stage group. Age, BMI and volume of the resected breasts were comparable in the two groups.

In line with our results in paper III, the best correlation for volume was seen with the plastic casts method (Orfit), while the 3-D volume measurements were too high. The final volume of the reconstructed breasts and filling frequencies did not differ statistically between the groups. A majority of the patients in both groups (17 out of 20) underwent breast reduction/mastopexy of the contralateral breast.

In the one-stage group, 14 out of 20 (70%) women were not satisfied with the aesthetic result compared to 2 out of 20 (10%) women in the two-stage group. This difference between the groups in terms of corrective surgery was highly significant,  $p=0.0002$ . The 14 unsatisfied patients in the one-stage group underwent a capsulotomy/ectomy and replacement of the permanent expander implant with a form-stable implant. Additional abdominal advancement was performed in eight of these patients in order to create a better definition of the inframammary fold and ptosis. Three of the patients also had augmentation on the contralateral side to achieve symmetry. Moreover, 3 of these 14 patients required a third operation because of asymmetries when the final outcome was evaluated at follow-up. The two patients in the two-stage group had corrective surgery because of an unduly large implant in one case and a too lateral placement of the implant in the other. The two-dimensional calculations of the upper and lower poles between the breasts demonstrated better symmetry in the two-stage group. The expert panel disagreed with the indication for revision surgery in 2 of the 14 patients who had revision in the one-stage group. Plastic surgeons considered that the main issue for corrective surgery was upper pole fullness and poor ptosis, which was in line with our objective two-dimensional analysis.

The complication rate was low among the 40 evaluated patients. Two seromas with superficial infections occurred in the one-stage group compared to one in the two-stage group and could be cured with aspiration and oral antibiotics.

The patients', the expert and lay people panels all gave high scores for the final aesthetic results. The patients were most satisfied, followed by the experts and then the lay people. The lowest scores were seen in the one-stage group before revision. Statistically significant differences ( $p < 0.005$ ) in patient satisfaction before and after corrective surgery were found in the one-stage group for the parameters shape, size, symmetry and patient's overall aesthetic result (Figure 11).

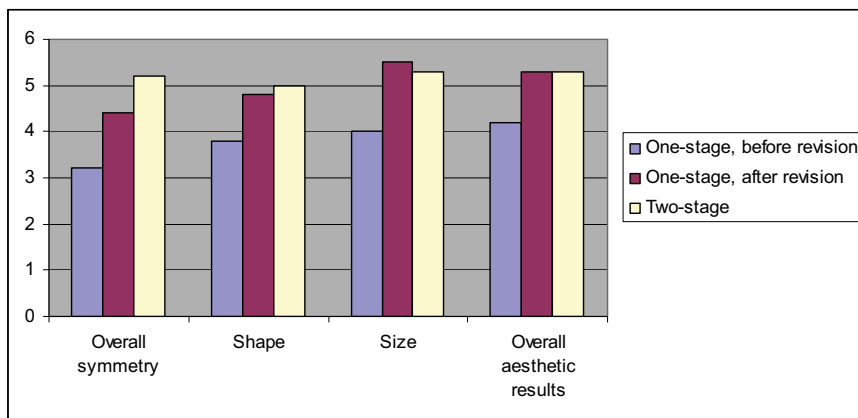


Figure 11. Patient's opinion regarding aesthetic outcome (rated 1-6, 1=very bad, 6=very good).

Pre- and postoperative SF-36 scores for both groups and an age-adjusted reference norm group are presented in Figure 12. Compared to the norm group, the scores for bodily pain were higher in both groups. The scores for the last three domains measuring emotional well-being were statistically significantly lower preoperatively in both groups compared to the norm group. At follow-up, the study groups had statistically significantly improved their scores and the score for bodily pain remained higher. Postoperatively, the two-stage group showed a higher level for emotional role functioning but the difference was not statistically significant.

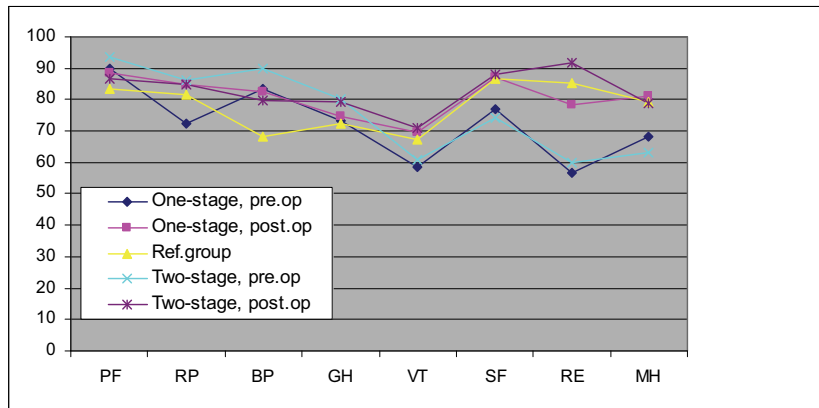


Figure 12. SF-36 health profile comparing pre and postoperatively results from both groups compared to aged matched norm group.  
 Pre.op = preoperatively, post.op = postoperatively. Norm group=Ref.group. PF= physical function, RP= physical role functioning, BP= bodily pain, GH=general health, VT= vitality, SF= social functioning, RE= emotional role functioning, MH= mental health.



## DISCUSSION

---

### *Paper I*

To the best of my knowledge, no prospective randomized studies have been published that address IBR's oncological safety. There are several retrospective studies regarding IBR and the rate of LR but just a few of them are cohort studies with a controlled design (Table IV) [16, 17, 19, 20, 23, 25, 28, 30, 31, 53, 111-114].

References	Tumour stage	Study period	Number of patients / control group	Follow-up (month)	Local recurrences / control group
Johanson et al, 1989	0-III	1980-86	118	28	6 %
Noone et al, 1994	0-III	1979-88	306	76	5,2 %
Slavin et al, 1994	1-IV	1982-90	161	65	11 %
Newman et al, 1998	I-II	1986-93	372	50	6,2 %
Ringberg et al, 1999	I-III	1980-94	79	43	5 %
Kroll et al, 1999	I-II	1986-90	154	72	7 %
Vanderweyer et al, 2000	0-IV	1990-95	49 / 49	72	4,1 % / 2,0 %
Medina-Franco et al, 2002	I-IV	1986-97	173	73	4,5 %
Langstein et al, 2003	-----	1988-98	1694	96	2,3 %
Carlson et al, 2003	0-IV	1989-98	565	65	5,5 %
Sandelin et al, 2004	I-III	1990-96	203	60	6,5 %
Greenway et al, 2005	I-II	1984-04	225	49	1,7 %
McCarthy et al, 2008	I-III	1995-99	309 / 309	68	6,8 % / 8,1 %
Petit et al, 2008	I-III	1997-01	518 / 159	70	5,2 % / 9,4 %
Eriksen et al, 2011	I-III	1988-06	300 / 300	138	8,2 % / 9,0 %

Table IV. Local recurrences after immediate breast reconstruction, previously published studies.

In order to evaluate whether a reconstructive procedure could influence the oncological outcome, a retrospective cohort study was designed in which patients with invasive breast cancer undergoing IBR with implants were compared with a matched group of women operated with mastectomy alone. Its strength lay in the well-matched and representative patient material and the long follow-up (median 11.5 years). The study provides evidence that IBR with implants can be considered a safe procedure oncologically. No significant inter-group differences were found in the rates of local recurrence and regional recurrence, neither were there any differences in time to initiate adjuvant treatment, number of chemotherapy cycles, radiotherapy treatment or in detection mode for recurrences. The rate of distant metastases was significantly higher in the control group and the survival figures were better for the reconstructed group. These results are in line with other studies, possibly as a consequence of confounding factors such as socioeconomic status and selection bias in

inclusion criteria, as IBR was usually not recommended for overweight patients and smokers [30, 115]. One limitation was that although the two groups were well-matched, the IBR group included more lobular cancers and a higher proportion of hormone receptor-positive tumours, which could indicate an overrepresentation of favourable tumours and thereby better prognosis in the IBR group. On the other hand, lobular carcinoma does not have a better clinical outcome or survival rate compared with ductal carcinoma [116]. A statistical correction for hormonal receptor status did not alter the results regarding recurrences, but the difference in breast cancer mortality risk was no longer significant.

There are few prospective studies concerning the aesthetic advantages and disadvantages of IBR with and without irradiation and which alternative can be favourable in the long run. In our experience, IBR with implants can be combined with irradiation from an oncological point of view but the aesthetic results tend to be inferior compared to non-irradiated reconstructions [117-123]. Many authors favour autologous tissue reconstructions. However, these techniques are less well investigated regarding oncological safety and especially as immediate procedures. Moreover, complications are liable to be more frequent and might delay adjuvant treatment [12, 13, 124]. As a guide in decision-making, SN biopsy (pre- and peroperative) and core biopsy can be used to predict the need for postoperative adjuvant therapy [124, 125].

A review article on oncological aspects of breast reconstruction in 2005 concluded that there was a lack of high-quality evidence on how to advise women considering IBR and IBRs possible impact on adjuvant treatment and prognosis [12]. Since then, three long-term retrospective follow-up studies with controls, two of them with matched controls (including paper I) have been published together with two review articles all pointing in the same direction. IBR with implants can safely be offered to breast cancer women in the absence of contraindications [29-32].

### *Paper II*

This paper was an early evaluation of the crescent-shaped expander implant that had been introduced on the market just before. Patients operated with this new breast expander, in immediate as well as in delayed reconstructions, expressed great satisfaction with the reconstructed breast after expansion. However, most expander implants designed for a one-stage procedure failed to meet the patient's expectations since in most cases a satisfactory

result required more than one operation. Unfortunately, the crescent-shaped expander could not be used as a permanent implant because of the configuration of the central magnetic filling port, which is made of metal and could interfere with MRI investigation. In contrast to traditional filling ports, we did not encounter problems as rotation, pain, or difficulties in localising the port. The results suggested that, compared to round and anatomically shaped expanders, the crescent-shaped expander gave a more natural shape, with less fullness of the upper pole and good ptosis. To find out whether or not these results could be verified, a methodological study (paper III) and a prospective randomised study (paper IV) were designed.

### *Paper III*

A methodological study was designed to evaluate new objective 3-D methods for measuring breast volume and shape and to compare them with traditional techniques.

Collaboration was initiated with Professor Stefan Jonson at the Royal Institute of Technology (KTH) and photographers at the Department of Medical Imaging, Karolinska University Hospital. The idea was to create 3-D images based on stereo photographs and to produce a new program for calculating breast volume and shape. This unfortunately proved much more difficult than expected and did not come about. Meanwhile a private company (Alicona) gave us permission to calculate breast volume from stereophotographs of six patients' images using the 3-D MeX computer program. The calculated results from the 3-D MeX program were compared with MRI, plastic casts and cups, and a 3-D laser scanner (acquired by Karolinska University Hospital in 2009). Compared to 3-D laser scan, the 3-D MeX method gave a slightly better correlation with the true values of breast volume, possibly because this method was more sensitive in recognising the convexity of the thoracic wall.

Earlier tests of the accuracy and reproducibility of 3-D evaluation have indicated a good potential. Our data suggest, however, that the method's accuracy as regards aspects of volume is questionable [104].

The findings confirmed that the method with plastic casts was easy to perform, delivered high accuracy and was inexpensive as the same material could be used for several evaluations. The plastic cups may be useful for estimating the volume of the female breast as data were in fairly good agreement with the true volume.

Traditional methods gave little or no information about the shape or contour of the breast. A two-dimensional sagittal section from 3-D images produced a contour of the breasts, permitting a numerical calculation of differences between their upper and lower poles. Numerical 3-D differences between the breasts could also be calculated with the Geomagic software program but such 3-D calculations could not be obtained that were reproducible. This may have been due to the complexity of the program, which had just been introduced at the Department of Medical Imaging. This could be a promising method for future studies. The introduction of 2- and 3-D scanning techniques added new dimensions to the evaluation of shape and volume but the data on volume should be interpreted with caution.

#### *Paper IV*

Various types of breast implants have been developed and evaluated in recent years. The overall aim of reconstructive surgery in breast cancer patients has been to improve the patient's quality of life and satisfaction with the outcome, using as few operations as possible [3, 7, 8, 92-95].

The main problems with traditional implants, both round and anatomically shaped, have been the occurrence of upper pole fullness and a lack of ptosis, while the crescent-shaped implant seemed to be capable of conferring a more natural shape [36]. A prospective randomised study was designed to determine to what extent the round Becker 25 expander implant could meet patients' expectations as a one-stage procedure compared with the two-stage crescent-shaped expander.

The strength of this study was its randomised design with two groups that were comparable regarding age, BMI and breast volume. Another strength was that the aesthetic outcome was evaluated on the basis of both objective and subjective data.



The results confirmed that the round permanent expander implant could not meet neither the patients' nor the surgeons' expectations as a one-stage procedure; the difference between the two groups in the number of reoperations was highly statistically significant. These results demonstrated the necessity of a two-stage procedure for achieving a good aesthetic outcome. The patients in the one-stage group were subjected to more advanced secondary surgery than those in the two-stage group, for whom abdominal advancement and augmentation were not required to achieve a satisfactory result.

The data further showed that patients in the two groups were equally satisfied with the final results after corrective surgery, except that final symmetry was significantly better in the two-stage group. The patients expressed the greatest satisfaction, followed by the experts and then the lay people.

In this study we also evaluated quality of life pre- and postoperatively in both groups and compared the results with an age-related reference group. Both groups scored higher on physical functioning and bodily pain than the reference group, which was in line with other studies and to be expected [126, 127]. The present data indicated that both groups recovered well from the low preoperative scores for emotional well-being and vitality. The two-stage group experienced better emotional role functioning than the one-stage group but the number of patients was too small to establish statistical significance.



## CONCLUSIONS

---

- In the absence of contraindications, immediate breast reconstruction with implants can be offered to and performed on patients with invasive breast cancer without any negative effect on oncological safety.
- Low-cost plastic cast measurement gave more exact values for breast volume than various methods for 3-D measurement. However, more advanced 3-D technology may prove to be an important and useful technique for the objective evaluation of reconstructive breast surgery. Shape can be measured objectively by two-dimensional technique based on 3-D laser scanning.
- The round permanent expander method failed to serve as a one-stage procedure, mostly due to upper pole fullness and lack of ptosis. The crescent two-stage expander method gave a more natural shape of the breast; both the patients and the panels of experts and lay people scored highest for shape and symmetry. Quality of life was significantly improved 1.5 years postoperatively in both groups, with no major differences between the groups.



## FUTURE PERSPECTIVES

---

This thesis is based on clinical questions raised in a breast surgeon's daily work with breast cancer women in need of a mastectomy.

Early studies showed that a mastectomy left 30 % of the women with problems of reduced self-esteem, depression, poor sleep and increased anxiety [128]. National guidelines state that in the absence of contraindications, these women should be offered breast reconstruction. Both IBR and delayed reconstruction are slowly being used more frequently. Despite the advantages of IBR, a majority of reconstructions are performed as a delayed procedure. The trend is not uniform: IBR is chosen by 20 % of the patients in Stockholm compared to 6 % in the rest of Sweden, indicating differences in information and/or demand [91].

There is an ongoing debate about which reconstructive method is most suitable economically, aesthetically and oncologically. One of the factors in this debate is the increasing use of post-mastectomy radiotherapy [29, 32, 117-123, 129, 130].

The tradition at Karolinska University Hospital has been that, in the absence of contraindications, women in need of a mastectomy are offered an IBR [28, 131]. Advanced surgery with flap technique has not been recommended as a primary procedure for breast cancer. One in three IBR reconstructions has been accompanied by radiotherapy even though this impairs the reconstruction as a result of more capsular contraction and inferior aesthetic results. Compared with mastectomy alone, however, even a poor result with IBR with implants can be a better starting-point for a second procedure.

It is not clear that IBR with implant is invariably the best alternative for women seeking breast reconstruction. Some studies have shown that in the long run, implant-based reconstructions are less aesthetically satisfactory than autologous tissue, but all do not agree on this issue [71, 124, 131, 132].

Still, since implant-based reconstruction probably will be frequently used in the future it is important to continue the development of new implants and to evaluate these in all important aspects. There is no universal solution; one implant does not suit every patient. Moreover, women considering IBR with autologous reconstruction should be included in studies until we know more about the oncological safety of these procedures. Preoperative mapping can be used to predict the risk of adjuvant treatment [124, 125].

Today, breast surgery and reconstructive surgery provide a variety of options, which makes it more difficult but important to tailor surgery, as well as the oncological treatment, to the individual patient (donor site, preferences, expectations, mental health). As each woman is unique, we need to be familiar with all the available reconstructive methods and be properly informed about our patients' mental and social situation. When the diagnosis of breast cancer is presented to them, patients may be disinclined to accept a reconstructive procedure because this aspect may not be their first concern. Patients should have one separate consultation for information about the advantages and disadvantages of the various forms of reconstruction and have time to consider them before the decision is made at a second visit.

For two years now, the four hospitals in Stockholm at which breast and reconstructive breast surgery are performed (Södersjukhuset, S:t Göran, Danderyd and Karolinska) have regular meetings to discuss issues connected with reconstructive surgery, for example, registration of results and complications, possible future studies, education and accreditation of reconstructive/oncoplastic breast surgeons.

Further education in this field is highly important for breast and plastic surgeons to enable us to meet patients' wishes with the best individual recommendations.

Further studies of reconstructive breast surgery are needed with PRO questionnaires, methods for objective measurements and aspects on oncological safety. Prospective randomised studies are admittedly difficult but not impossible to perform.

## SWEDISH SUMMARY

---

**Titel: Primär rekonstruktion med implantat vid bröstcancer- en studie av onkologisk säkerhet och estetiskt resultat.**

Behandlingen av bröstcancer har genomgått stora förändringar de senaste decennierna från att initialt avlägsna hela bröstet (mastektomi) till bröstbevarande kirurgi. Förbättrad kunskap om bröstcancers tumörbiologi har bidragit till utveckling av potenta kemo- och antihormonella behandlingsstrategier i kombination med strålbehandling.

Trots införandet av bröstbevarande kirurgi, som utförs i c:a 50-60 %, rekommenderas årligen mastektomi hos ca 3000 kvinnor i Sverige. Kvinnor som genomgår mastektomi löper större risk att få nedsatt självkänsla, sömnsvårigheter, ökat ångest, depression samt sexuella problem. I enlighet med det nationella vårdprogrammet bör alla kvinnor som rekommenderas mastektomi erbjudas rekonstruktion av bröstet om inget medicinskt hinder föreligger. De psykosociala vinsterna samt de kosmetiska fördelarna med en bröstrekonstruktion är väl dokumenterade.

Den onkologiska säkerheten vid primär rekonstruktion har studerats i retrospektiva studier med varierande uppföljning och i de flesta fall utan jämförande kontroller. Resultaten har talat för att den lokala återfallsfrekvensen förefaller vara låg och jämförbar med kvinnor som genomgått operation utan rekonstruktion. Trots mer än 20 års nationell och internationell erfarenhet med primär bröstrekonstruktion med implantat råder fortfarande en viss osäkerhet både bland patienter och hos sjukvårdspersonal beträffande den onkologiska säkerheten. Vid fall med avancerad bröstcancer och i fall med planerad strålbehandling är indikationen för primär rekonstruktion oklar. Detta leder till att patienterna får varierande och otydlig information. Primär rekonstruktion med implantat är i Sverige ett förstahandsalternativ. Det finns många olika implantat som är kommersiellt tillgängliga. Nackdelen med de flesta implantat är att det rekonstruerade bröstet blir för fylligt i den övre delen och saknar det naturliga hänget (ptos) jämfört med det friska bröstet.

Syftet med *studie I* var att studera om primär rekonstruktion med implantat kunde påverka återfallsfrekvens och överlevnad samt att undersöka om tiden till onkologisk tilläggsbehandling fördröjdes. I en retrospektiv långtidsuppföljning (median 11,5 år) jämfördes 300 patienter med invasiv bröstcancer opererade med mastektomi och samtidig rekonstruktion med implantat med 300 matchade patienter opererade med enbart mastektomi. Det förelåg inga signifikanta skillnader mellan grupperna beträffande antalet lokala och regionala återfall samt tid till behandling. Färre fjärrmetastaser samt bättre överlevnad förelåg i den rekonstruerade gruppen vilket kan bero på en selektion av patienter i den rekonstruerade gruppen.

I en pilotstudie (*studie II*) belystes resultaten av bröstrekonstruktion med ett nytt implantat med formen av en halvmåne (crescentformat implantat). Syftet med det nya implantatet var att återskapa en mer naturlig form och symmetri då den specifikt expanderar den nedre delen av bröstet. Den crescentformade expandern opereras i ett två-steps förfarande och ersätts efter expansion med ett permanent anatomiskt implantat. Studien gav, trots att den var liten, ett intryck av att tvåstegsmetoden gav ett bättre estetiskt resultat jämfört med traditionella expanderimplantat.

*Studie III* var ett metodarbete som validerade olika mätmetoder för bröstvolym och form hos sex patienter som skulle genomgå en rekonstruktion samt hos sex patienter som genomgått en rekonstruktion. Resultaten visade stor variation mellan de olika mätmetoderna, där magnetrontgen och 3-dimensionell teknik visade högre volymer jämfört med äldre enklare metoder som vanliga skålar i plast och formbar plast vilken gav den mest exakta volymkattningen. Konturskillnader mellan bröstet mättes och kvantifierades med två-dimensionell teknik baserat från 3-D bilder.

För att konfirmera erfarenheterna från *studie II* genomfördes en prospektiv randomiserad studie (*studie IV*) där patienter slumpmässigt selekterades till att opereras med den crescentformade två-stegsmodellen eller med en rund, permanent, traditionell expander. Fyrtio patienter, 20 i varje grupp, evaluerades. Mätmetoder redovisade i studie III användes för utvärdering. Dessutom utvärderade patienterna själva samt en panel bestående av lekmän och plastikkirurger de kosmetiska resultaten. Det permanenta, runda implantatet fallerade som en enstegsmetod och krävde reoperationer i 70% av fallen. Två-stegs metoden med det crescentformade implantatet gav bäst form och symmetri.



Livskvalitet utvärderades med hjälp av SF-36 som är ett validerat frågeformulär där de studerade patienterna jämfördes med en åldersrelaterad normalbefolkning. Resultaten visade att de rekonstruerade patienterna återhämtade sig 1,5 år efter operationen och inga större skillnader kunde ses mellan de två grupperna.

Sammanfattning: Primär bröstrekonstruktion med implantat kan erbjudas patienter med bröstcancer utan negativ inverkan på den onkologiska säkerheten. Tvåstegsförfarande med den crescentformade expandern gav ett bättre resultat jämfört med traditionella enstegsimplantat. De äldre enklare teknikerna gav de mest exakta volymsbedömningarna jämfört med ny 3-D teknik som dock kunde användas som underlag för två-dimensionell konturbedömning.



## REFERENCES

---

1. www.socialstyrelsen.se, National guidelines for breast cancer care 2009, statistics-health and medical care.
2. Lidgren M. Health economics of breast cancer. PhD thesis, Karolinska Institutet, 2007.
3. Dean C, Chetty U, Forrest AP. Effects of immediate breast reconstruction on psychosocial morbidity after mastectomy. *Lancet*, 1983; 1: 459-462.
4. Schover LR. Sexuality and body image in younger women with breast cancer. *J Natl Cancer Inst Monogr*, 1994; 16:177-182.
5. Han J, Grothuesmann D, Neises M, Hille U, Hillemanns P. Quality of life and satisfaction after breast cancer operation. *Arch Gynecol Obstet*, 2010; 282:75-82.
6. Nano MT, Gill PG, Kollias J, Bochner MA, Malycha P, Whinefield HR. Psychological impact and cosmetic outcome of surgical breast cancer strategies. *ANZ J Surg*, 2005; 75: 940-947.
7. Elder EE, Brandberg Y, Björklund T, Rylander R, Lagergren J, Jurell G, Wickman M, Sandelin K. Quality of life and patient satisfaction in breast cancer patients after immediate reconstruction: a prospective study. *Breast*, 2005; 14:201-208.
8. Rowland JH, Holland JC, Chaglassian T, Kinne D. Psychological response to breast reconstruction. Expectations for and impact on postmastectomy functioning. *Psychosomatics*, 1993; 34:241-250.
9. Rosenqvist S, Sandelin K, Wickman M. Patient's psychological and cosmetic experience after immediate breast reconstruction. *Eur J Surg Oncol*, 1996; 22:262-266.
10. Bowman CC, Lennox PA, Clugston PA, Courtemanche DJ. Breast reconstruction in older women: should age be an exclusion criterion? *Plast Reconstr Surg*, 2006; 118:16-22.
11. Fernández-Delgado J, López-Pedraza MJ, Blasco JA, Andradás-Aragones E, Sánchez-Méndez JI, Sordo-Miralles G, Reza MM. Satisfaction with and psychological impact of immediate and deferred breast reconstruction. *Ann Oncol*, 2008; 19:1430-1434.
12. Taylor CW, Horgan K, Dodwell D. Oncological aspects of breast reconstruction. *Breast*, 2005; 14:118-130.
13. Lewis RS, Kontos M. Autologous tissue immediate breast reconstruction: desired but oncologically safe? *J Clin Pract*, 2009; 63:1642-1646.

14. Slavin SA, Schnitt SJ, Duda RB, Houlihan MJ, Koufman CN, Morris DJ, Troyan SL, Goldwyn RM. Skin-sparing mastectomy and immediate reconstruction: oncologic risks and aesthetic results in patients with early-stage breast cancer. *Plast Reconstr Surg*, 1998; 102:49-62.
15. Rainsbury RM. Skin-sparing mastectomy. *Br J Surg*, 2006; 93:276-281.
16. Kroll SS, Khoo A, Singletary SE, Ames FC, Wang B-G, Reece GP et al. Local recurrence risk after skin-sparing and conventional mastectomy: a 6-year follow up. *Plast Reconstr Surg*, 1999; 104:421-425.
17. Johnson CH, Van Heerden JA, Donohue JH, Martin JK, Jr, Jackson IT, Ilstrup DM. Oncological aspects of immediate breast reconstruction following mastectomy for malignancy. *Arch Surg*, 1989; 124:819-824.
18. O'Brian W, Hasselgren PO, Hummel RP, Coith R, Hyams D, Kurtzman L, Neale HW. Comparison of postoperative wound complications and early cancer recurrence between patients undergoing mastectomy with or without immediate breast reconstruction. *Am J Surg*, 1993; 166:1-5.
19. Slavin SA, Love SM, Goldwyn RM. Recurrent breast cancer following immediate reconstruction with myocutaneous flaps. *Plast Reconstr Surg*, 1994; 93:1191-1207.
20. Noon RB, Frazier TG, Noone GC, Blanchet NP, Murphy JB, Rose D. Recurrence of breast carcinoma following immediate reconstruction: A 13-year review. *Plast Reconstr Surg*, 1994; 93:96-108.
21. Singletary SE. Skin-sparing mastectomy with immediate breast reconstruction: the M. D. Anderson Cancer Center experience. *Ann Surg Oncol*, 1996; 3: 411-416.
22. Newman LA, Kuerer HM, Hunt KK, Ames FC, Ross MI, Theriault R et al. Feasibility of immediate breast reconstruction for locally advanced breast cancer. *Ann Surg Oncol*, 1999; 6:671-675.
23. Vandeweyer E, Hertens D, Nogaret JM, Deraemaeker R. Immediate breast reconstruction with saline-filled implants: no interference with the oncologic outcome? *Plast Reconstr Surg*, 2001; 107:1409-1412.
24. Allweis TM, Boisvert ME, Otero SE, Perry DJ, Dubin NH, Priebe DA. Immediate reconstruction after mastectomy for breast cancer does not prolong the time to starting adjuvant chemotherapy. *Am J Surg*, 2002; 183:218-221.
25. Langstein HN, Cheng MH, Singletary SE, Robb GL, Hoy E, Smith TL, Kroll SS. Breast cancer recurrence after immediate reconstruction: Patterns and significance. *Plast Reconstr Surg*, 2003; 111:712-722.
26. Murphy RX Jr, Wahhab S, Rovito PF, Harper G, Kimmel SR, Kleinman LC, Young MJ. Impact of immediate reconstruction on the local recurrence of breast cancer after mastectomy. *Ann Plast Surg*, 2003; 50:333-338.

27. Knottenbelt A, Spauwen PH, Wobbes T. The oncological implications of immediate breast reconstruction. *Eur J Surg Oncol*, 2004; 30:829-833.
28. Sandelin K, Wickman M, Billgren AM. Oncological outcome after immediate breast reconstruction for invasive breast cancer: a long-term study. *Breast*, 2004; 13:210-218.
29. Patani N, Mokbel K. Oncological and aesthetic considerations of skin-sparing mastectomy. *Breast Cancer Res Treat*, 2008; 111:391-403.
30. McCarthy CM, Pusic AL, Sclafani L, Buchanan C, Fey JV, Disa JJ, Mehrara BJ, Cordeiro PG. Breast cancer recurrence following prosthetic postmastectomy reconstruction: Incidence, detection, and treatment. *Plast Reconstr Surg*, 2008; 121:381-388.
31. Petit JY, Gentilini O, Rotmensz N, Rey P, Rietjens M, Garusi C et al. Oncological results of immediate breast reconstruction: long term follow-up of a large series at a single institution. *Breast Cancer Res Treat*, 2008; 112:545-549.
32. Lanitis S, Tekkis PP, Sgourakis G, Dimopoulos N, Al Mufti R, Hadjiminis DJ. Comparison of skin-sparing mastectomy versus non-skin-sparing mastectomy for breast cancer: A meta-analysis of observational studies. *Ann Surg*, 2010; 251:632-639.
33. [www.wikipedia.org/wiki/Breast\\_reconstruction](http://www.wikipedia.org/wiki/Breast_reconstruction).
34. McGeorge DD, Mahdi S, Tsekouras A. Breast reconstruction with anatomical expanders and implants: our early experience. *Br J Plast Surg*, 1996; 49:352-357.
35. Mahdi S, Jones T, Nicklin S, McGeorge DD. Expandable anatomical implants in breast reconstructions: a prospective study. *Br J Plast Surg*, 1998; 51:425-430.
36. Rigotti G, Marchi A. New approach in immediate expander-prosthesis breast reconstruction: 267 consecutive cases using semilunar vs traditional expanders, different patterns of skin incision and pure-string wound closure. *Br J Plast Surg*, 2002; 24:328-332.
37. Bray F, Sankila R, Ferlay J, Parkin DM. Estimates of cancer incidence and mortality in Europe in 1995. *Eur J Cancer*, 2002; 38: 99-166.
38. Leong SP, Shen ZZ, Liu TJ, Agarwal G, Tajima T, Paik NS et al. Is breast cancer the same disease in Asian and Western countries? *World J Surg*, 2010; 34:2308-2324.
39. [www.cancerfonden.se](http://www.cancerfonden.se), Cancer in numbers, 2009.
40. [www.comparatorreports.se](http://www.comparatorreports.se) Wilking N, Kasteng F. A review of breast cancer care and outcomes in 18 countries, October 2009.

41. Newman B, Austin MA, Lee M, King MC. Inheritance of human breast cancer: evidence for autosomal dominant transmission in high-risk families. *Proc Natl Acad Sci USA*, 1988; 85:3044-3048.
42. Claus EB, Schildkraut JM, Thompson WD, Risch NJ. The genetic attributable risk of breast and ovarian cancer. *Cancer*, 1996; 77:2318-2324.
43. Vetto J, Pommer R, Schmidt W, Wachtel M, DuBois P, Jones M, Thurmond A. Use of "triple test" for palpable breast lesions yields high diagnostic accuracy and cost savings. *Am J Surg*, 1995; 169:519-522.
44. Clarke M, Collins R, Darby S, Davies C, Elphinstone P, Evans E et al. Effects of radiotherapy and of differences in the extent of surgery for early breast cancer on local recurrence and 15-year survival: an overview of the randomised trials, *Lancet*, 2005; 366: 2087-2106.
45. Hennessy BT, Gonzalez-Angulo AM, Hortobagyi GN, Cristofanilli M, Kau SW et al. Disease-free and overall survival after pathologic complete disease remission of cytologically proven inflammatory breast carcinoma axillary lymph node metastases after primary systemic chemotherapy. *Cancer*, 2006; 106:1000-1006.
46. Veronesi U, Paganelli G, Viale G, Luini A, Zurrada S, Galimberti V et al. A randomized comparison of sentinel-node biopsy with routine axillary dissection in breast cancer. *N Engl J Med*, 2003; 349:546-553.
47. Bergkvist L, Frisell J. Swedish Breast Cancer Group; Swedish Society of Breast Surgeons. Multicentre validation study of sentinel node biopsy for staging in breast cancer. *Br J Surg*, 2005; 92: 1221-1224.
48. Celebioglu F, Sylvan M, Perbeck L, Bergkvist L, Frisell J. Intraoperative sentinel lymph node examination by frozen section, immunohistochemistry and imprint cytology during breast surgery-a prospective study. *Eur J Cancer*, 2006; 42: 617-620.
49. Sobin LH, Gospodarowicz MK, Wittekind Ch. Eds. *TNM Classification of Malignant Tumors*, 7th ed. Wiley-Blackwell, Oxford 2009.
50. Bland KI, Menck HR, Scott-Conner CE, Morrow M, Winchester DJ, Winchester DP. The national cancer data base 10 years survey of breast carcinoma treatment at hospitals in the United States. *Cancer*, 1998; 83:1262-1273.
51. Fredriksson I, Liljegren G, Arnesson LG et al. Local recurrence in the breast after conservative surgery-a study of prognosis and prognostic factors in 391 women. *Eur J Cancer*, 2002; 38:1860-1870.
52. Rutgers EJ, Meijnen P, Bonnefoi H. Clinical trials update of the European Organization for Research and Treatment of Cancer Breast Cancer Group. *Breast Cancer Res*, 2004; 6: 165-169.

53. Carlson GW, Styblo TM, Lyles RH, Bostwick J, Murray DR, Staley CA, Wood WC. Local recurrence after skin-sparing mastectomy: tumor biology or surgical conservatism? *Ann Surg Oncol*, 2003; 10:108-12.
54. Rowell NP. Are mastectomy resection margins of clinical relevance? A systematic review. *Breast*, 2010; 19:14-22
55. Breasted JH, *The Edwin Smith surgical papyrus*. The University of Chicago Press, Chicago, III, 1930.
56. [www.randomhistory.com](http://www.randomhistory.com), History of breast cancer.
57. Pearcy L. 'Galen's Pergamum,' *Archaeology*, 1985; 38:633-639.
58. Olson, James. *Bathsheba's Breast: Women, Cancer, and History*. Baltimore: John Hopkins Press, 2002.
59. Halsted WS. The results of operations for cure of cancer of the breast performed at the Johns Hopkins Hospital from June 1889 to January 1894. *Ann Surg*, 1894; 20:497-555.
60. Fisher B, Bauer M, Margolese R, Poisson R, Pilch Y, Redmond C et al. Five-year results of a randomized clinical trial comparing total mastectomy and segmental mastectomy with or without radiation in the treatment of breast cancer. *N Engl J Med*, 1985; 312:665-673.
61. Veronesi U, Saccozzi R, Del Vecchio M, Banfi A, Clemente C, De Lena M et al. Comparing radical mastectomy with quadrantectomy, axillary dissection, and radiotherapy in patients with small cancers of the breast. *N Engl J Med*, 1981; 305: 6-11.
62. Cabanas RM. An approach for the treatment of penile carcinoma. *Cancer*, 1977; 39: 456-466.
63. Giuliano AE, Kirgan DM, Guenther JM, Morton DL. Lymphatic mapping and sentinel lymphadenectomy for breast cancer. *Ann Surg*, 1994; 220: 391-401.
64. Krag DN, Weaver DL, Alex JC, Fairbank JT. Surgical resection and radiolocalization of the sentinel lymph node in breast cancer using a gamma probe. *Surg Oncol*, 1993; 2: 335-340.
65. Losken A, Jurkiewicz MJ. History of breast reconstruction. *Breast Dis*, 2002; 16: 3-9.
66. Czerny V and the beginnings of breast reconstruction. *Plast Reconstr Surg* 1978; 61:673-681.
67. Croin TD, Gerow FJ. *Augmentation Mammoplasty: A new natural feel prosthesis*, Transactions of the Third International Congress of Plastic Surgery, Amsterdam. Excerpta Medica Foundation, 1964: 41-49.

68. Arion HG. "Retromammary prosthesis". *C R Soc Fr Gynecol* 1965; 5.
69. Becker H. Breast reconstruction using an inflatable breast implant with detachable reservoir. *Plast Reconstr Surg*, 1984; 73:678-683.
70. [www.emedicine.medscape.com](http://www.emedicine.medscape.com), Brody GS. Breast implants, safety and efficacy of silicon.
71. Alderman AK, Kuhn LE, Lowery JC, Wilkins EG. Does patient satisfaction with breast reconstruction change over time? Two-year results of the Michigan Breast Reconstruction Outcome Study. *J Am Coll Surg*, 2007; 204:7-12.
72. Bodin F, Zink S, Lutz JC, Kadoch V, Wilk A, Bruant-Rodier C. Which breast reconstruction procedure provides the best long-term satisfaction? Article in French. *Ann Chir Plast Esthet*, 2010; 55:547-552.
73. Olivari N. The latissimus flap. *Br J Plast Surg*, 1976; 29:126-128.
74. Schneider WJ, Hill HL Jr, Brown RG. Latissimus dorsi myocutaneous flap for breast reconstruction. *Br J Plast Surg*, 1977; 30: 277-281.
75. Eriksen C, Stark B. The latissimus dorsi flap-still a valuable tool in breast reconstruction: report of 32 cases. *Scand J Plast Reconstr Surg*, 2008; 42:132-137.
76. Sinna R, Delay E, Garson S, Delaporte T, Toussoun G. Breast fat grafting (lipomodelling) after extended latissimus dorsi flap breast reconstruction: a preliminary report of 200 consecutive cases. *Plast Reconstr Aesthet Surg*, 2010; 63:1769-1777.
77. Holmström H, Lossing C. The lateral thoracodorsal flap in breast reconstruction. *Plast Reconstr Surg*, 1986; 77:933-943.
78. Holmström H. The free abdominoplasty flap and its use in breast reconstruction. An experimental study and clinical case report. *Scand J Plast Reconstr Surg*, 1979; 13:423-427.
79. Hartrampf CR, Schefflan M, Black PW. Breast reconstruction with a transverse abdominal island flap. *Plast Reconstr Surg*, 1982; 69: 216-225.
80. Serletti JM. Breast reconstruction with the TRAM flap: pedicled and free. *J Surg Oncol*, 2006; 94:532-537.
81. Gill PS, Hunt JP, Guerra AB, Dellacroce FJ, Sullivan SK, Boraski J et al. A 10-year retrospective review of 758 DIEP flaps for breast reconstruction. *Plast Reconstr Surg*, 2004; 113:1153-1160.
82. Koshima I, Soeda S. Inferior epigastric artery skin flaps without rectus abdominis muscle. *Br J Plast Surg*, 1989; 42: 645-648.



83. Allen RJ, Treece P. Deep inferior epigastric perforator flap for breast reconstruction. *Ann Plast Surg*, 1994; 32: 32-38.
84. Arnez ZM, Khan U, Pogorelec D, Planinsek F. Breast reconstruction using the free superficial inferior epigastric artery (SIEA) flap. *Br J Plast Surg*, 1999; 52: 276-279.
85. Garvey PB, Buchel EW, Pockaj BA, Casey WJ 3 rd, Hernández JL, Samson TD. DIEP and pedicled TRAM flaps: a comparison of outcomes. *Plast Reconstr Surg*, 2006; 117:1711-1719.
86. Papp C, Windhofer C, Gruber S. Breast reconstruction with the fasciocutaneous infragluteal free flap. *Ann Plast Surg*, 2007; 58:131-136.
87. Kaplan JL, Allen RJ, Guerra A, Sullivan SK. Anterolateral thigh flap for breast reconstruction: review of the literature and case reports. *J Reconstr Microsurg* 2003; 19:63-68.
88. Wechselberger G, Schoeller T. The transverse myocutaneous gracilis free flap: a valuable tissue source in autologous breast reconstruction. *Plast Reconstr Surg*, 2004; 114: 69-73.
89. Chun YS, Verma K, Rosen H, Lipsitz S, Morris D, Kenney P, Eriksson E. Implant-based breast reconstruction using acellular dermal matrix and the risk of postoperative complications. *Plast Reconstr Surg*, 2010; 125:429-436.
90. Agha-Mohammadi S, De La Cruz C, Hurwitz DJ. Breast reconstruction with alloplastic implants. *J Surg Oncol*, 2006; 94: 471-478.
91. [www.karolinska.se/oc](http://www.karolinska.se/oc), national annual report.
92. Cella DF, Tulsky DS. Quality of life in cancer: definition, purpose, and method of measurement. *Cancer Invest*, 1993; 11:327-336.
93. Chen CM, Cano SJ, Klassen AF, King T, McCarthy C, Cordeiro PG et al. Measuring quality of life in oncologic breast surgery: a systematic review of patient-reported outcome measures. *Breast J*, 2010; 16:587-597.
94. Nicholson RM, Leinster S, Sassoon EM. A comparison of the cosmetic and psychological outcome of breast reconstruction, breast conserving surgery and mastectomy without reconstruction. *Breast J*, 2007; 16:396-410.
95. Al-Ghazal SK, Sully L, Fallowfield L, Blamey RW. The psychological impact of immediate rather than delayed breast reconstruction. *Eur J Surg Oncol*, 2000; 26:17-19.
96. Curran D, van Dongen JP, Aaronson NK, Kiebert G, Fentiman IS, Mignolet F, Bartelink H. Quality of life of early-stage breast cancer patients treated with radical mastectomy or breast-conserving procedures: results of EORTC Trial 10801. The European Organization for Research and Treatment of Cancer (EORTC), Breast Cancer Co-operative Group (BCCG). *Eur J Cancer*, 1998; 34:307-314.

97. Saulis AS, Mustoe TA, Fine NA. A retrospective analysis of patient satisfaction with immediate postmastectomy breast reconstruction: comparison of three common procedures. *Plast Reconstr Surg*, 2007; 119:1669-1676.
98. Winter ZE, Thomson HJ. Assessing the clinical effectiveness of breast reconstruction through patient-reported outcome measures. *Br J Surg*, 2011; 98:323-325.
99. Harcourt DM, Rumsey NJ, Ambler NR, Cawthorn SJ, Reid CD, Maddox PR et al. The psychological effect of mastectomy with or without breast reconstruction: a prospective, multicenter study. *Plast Reconstr Surg*, 2003; 111: 1060-1068.
100. Bulstrode N, Bellamy E, Shrotria S. Breast volume assessment: comparing five different techniques. *Breast*, 2001; 10:117-123.
101. Noritaka I, Kenshin S, Hiroshi K, Masahiro W, Hiroki I, Hitoshi S. Quantitative analysis of the reconstructed breast using a 3-dimensional laser light scanner. *Ann Plast Surg*, 2006; 56:237-242.
102. Kovacs L, Eder M, Hollweck R, Zimmerman A, Settles M, Schneider A et al. Comparison between breast volume measurement using 3D surface imaging and classical techniques. *Breast*, 2007; 16:137-145.
103. Kovacs L, Yassouridis A, Zimmerman A, Brockman G, Wöhl A, Blaschke M et al. Optimization of 3-dimensional imaging of the breast region with 3-dimensional laser scanners. *Ann Plast Surg*, 2006; 56:229-236.
104. Kovacs L, Eder M, Hollweck R, Zimmerman A, Settles M, Schneider A et al. New aspects of breast volume measurement using 3-dimensional surface imaging. *Ann Plast Surg*, 2006; 57:602- 610.
105. Losken A, Seify H, Denson DD, Paredes AA, Carlson DW. Validating three-dimensional imaging of the breast. *Ann Plast Surg*, 2005; 54:471-478.
106. Tepper O, Choi M, Small K, Unger J, Davidson E, Rudolph L et al. An innovative three-dimensional approach to defining the anatomical changes occurring after short scar-medial pedicle reduction mammoplasty. *Plast Reconstr Surg*, 2008; 121:1875-1885.
107. Strömbeck JO, Malm M. Priority grouping in a waiting list of patients for reduction mammoplasty. *Ann Plast Surg*, 1986; 17:498-502.
108. Edsander-Nord A, Wickman M, Jurell G. Measurement of breast volume with thermoplastic casts. *Scand J Plast Reconstr Surg Hand Surg*, 1996; 30:129-132.
109. Tavassoli FA, Devilee P. WHO Classification of tumours: Pathology and genetics of tumours of the breast and female genital organs, 2003.

110. Elston CW, Ellis IO. Pathological prognostic factors in breast cancer. I. The value of histological grade in breast cancer: experience from a large study with long-term follow-up. *Histopathology*, 2002; 41:154-161.
111. Newman LA, Kuerer HM, Hunt KK, Kroll SS, Ames FC et al. Presentation, treatment, and outcome of local recurrence after skin-sparing mastectomy and immediate breast reconstruction. *Ann Surg Oncol*, 1998; 5: 620-626.
112. Ringberg A, Tengrup I, Aspegren K, Palmer B. Immediate breast reconstruction after mastectomy for cancer. *Eur J Surg Oncol*, 1999; 25: 470-476.
113. Medina-Franco H, Vasconez LO, Fix RJ, Heslin MJ, Beenken SW, Bland KI, Urist MM. Factors associated with local recurrence after skin-sparing mastectomy and immediate breast reconstruction for invasive breast cancer. *Ann Surg*, 2002; 235: 814-819.
114. Greenway RM, Schlossberg L, Dooley WC. Fifteen-year of skin-sparing mastectomy for stage 0 to 2 breast cancer. *Am J Surg*, 2005; 190: 918-922.
115. Bezuhly M, Temple C, Sigurdson LJ, Davis RB, Flowerdew G, Cook EF Jr. Immediate postmastectomy reconstruction is associated with improved breast cancer-specific survival: Evidence and new challenges from the surveillance, epidemiology, and end results database. *Cancer*, 2009; 115:4648-4654.
116. Arpino G, Bardou VJ, Clark GM, Elledge RM. Infiltrating lobular carcinoma of the breast: tumor characteristics and clinical outcome. *Breast Cancer Res*, 2004; 6:149-156.
117. Behranwala KA, Dua RS, Ross GM, Ward A, A'Hern R, Gui GP. The influence of radiotherapy on capsule formation and aesthetic outcome after immediate breast reconstruction using biodimensional anatomical expander implants. *J Plast Reconstr Aesthet Surg*, 2006; 59: 1043-1051.
118. Corderio PG, Pusic AL, Disa JJ, McCormick B, VanZee K. Irradiation after immediate tissue expander/implant breast reconstruction: outcomes, complications, aesthetic results, and satisfaction among 156 patients. *Plast Reconstr Surg*, 2004; 113:877-881.
119. McCormick B, Wright J, Corderio PG. Breast reconstruction combined with radiation therapy: Long-term risks and factors related to decision making. *Cancer J*, 2008; 14:264-268.
120. Koutcher L, Ballabdrud Å, Cordeiro PG, McCormick B, Hunt M, Van Zee KJ, Hudis C, Beal K. Postmastectomy intensity modulated radiation therapy following immediate expander-implant reconstruction. *Radiother Oncol*, 2010; 94:319-323.
121. Cordeiro PG, McCarthy CM. A single surgeon's 12-year experience with tissue expander/implant breast reconstruction: part I. A prospective analysis of early complications. *Plast Reconstr Surg*, 2006; 118:825-831.

122. Krueger EA, Wilkins EG, Strawderman M, Cederna P, Goldfarb S, Vicini FA, Pierce LJ. Complications and patient satisfaction following expander/implant breast reconstruction with and without radiotherapy. *Int J Radiat Oncol Biol Phys*, 2001; 49:713-721.
123. Kronowitz SJ, Robb GL. Radiation therapy and breast reconstruction: a critical review of the literature. *Plast Reconstr Surg*, 2009; 124:395-408.
124. Pomahac B, Recht A, May JW, Hergrueter CA, Slavin SA. New trends in breast cancer management: is the era of immediate breast reconstruction changing? *Ann Surg*, 2006; 244:282-288.
125. Christante D, Pommier SJ, Diggs BS, Samuelson BT, Truong A, Marquez C et al. Using Complications Associated With Postmastectomy Radiation and Immediate Breast Reconstruction to Improve Surgical Decision Making. *Arch Surg*, 2010; 145:873-878.
126. Sackey H, Sandelin K, Frisell J, Wickman M, Brandberg Y. Ductal carcinoma in situ of the breast. Long-term follow-up of health-related quality of life, emotional reactions and body image. *Eur J Surg Oncol*, 2010; 36:756-762.
127. Sprangers MA, Schwartz CE. Integrating response shift into health-related quality of life research: a theoretical model. *Soc Sci Med*, 1999; 48:1507–1515.
128. Meyer L, Aspegren K. Long-term psychological sequelae of mastectomy and breast conserving treatment for breast cancer. *Acta Oncol*, 1989; 28:13-8.
129. Motwani SB, Strom EA, Schechter NR, Butler CE, Lee GK, Langstein HN et al. The impact of immediate breast reconstruction on the technical delivery of postmastectomy radiotherapy. *Int J Radiat Oncol Biol Phys*, 2006; 66:76-82.
130. Khoo A, Kroll SS, Reece GP, Miller MJ, Evans GR, Robb GL et al. A comparison of resource costs of immediate and delayed breast reconstruction. *Plast Reconstr Surg*, 1998; 101:964-970.
131. Lagergren J, Jurell G, Sandelin K, Rylander R, Wickman M. Technical aspects of immediate breast reconstruction with implants: Five year follow up. *Scand J Plast Reconstr Surg Hand Surg*, 2005; 39:147-152.
132. Spear SL, Newman MK; Bedford MS, Schwartz KA, Cohen M, Schwartz JS. A Retrospective Analysis of Outcomes Using Three Common Methods for Immediate Breast Reconstruction. *Plast Reconstr Surg*, 2008; 122: 340-347.

## ACKNOWLEDGEMENTS

---

I wish to express my sincere gratitude to all patients, colleagues and friends. Without you this book would not have been possible. Especially, I would express appreciation to:

Birgit Stark, my main supervisor and dear friend, for your never-ending enthusiasm. I will never forget our early days back at Huddinge Hospital when you got me so inspired that every weekend I waited for Monday morning and a new day at work. I would also like to thank you for sharing your fantastic skills in the operating theatre with me.

Jan Frisell, my supervisor, dear friend and role model. For being the best chief and leader I could ever hope for, always optimistic and always supportive. I would also like to thank you for sharing your scientific knowledge and believing in me.

Kerstin Sandelin, my co-supervisor, for sharing the same ideas and your genuine interest in breast cancer patients and for being a pioneer in the field of primary breast reconstruction.

Göran Jurell, my former co-supervisor who has unfortunately passed away. Thank you for valuable support in the beginning of my research.

Leif Perbeck, the kindest person and colleague I know. For being a clinical mentor and sharing your excellent surgical skills and jokes with me.

Jan Zedenius, my mentor for support and encouragement and for introducing the “filofax” to me.

Marie Wickman, my co-author for clinical and research support. Martin Bäckdahl, Johan Westerdahl, Staffan Gröndal and other former heads of the Departments of Surgery, Breast and Endocrine Surgery and Reconstructive Plastic Surgery for supporting my clinical work and research project.

All my colleagues at the Department of Oncology, for excellent cooperation; I would especially like to thank Elisabet Lidbrink, also my co-author, for support.

All my colleagues at the Department of Reconstructive Plastic Surgery, especially Inkeri Schultz, Jakob Lagergren, Jessica Gahm, Petra Peterson, Filip Farnebo and Martin Halle for being the expert panel in paper IV.

The three musketeers; Hanna Fredholm, Cia Ihre-Lundgren and Irma Fredriksson, one for all, all for one! Do I have to say more; thank you all for many years of friendship and good work.

Emelie Nordstrand Lindgren, my co-author, and her helpful colleagues at the Department of Medical Imaging for patience and invaluable assistance with all images and 3-D measurements.

Kamilla Krawiec, my co-author, Elisabeth Berg and Hemming Johansson for your support and statistical analyses.

Catarina Bitcover, my college and friend, for your always positive support and your wonderful drawings, including the cover illustration.

Amelia Chiorescu, Jana de Boniface, Helena Sackey, Fredrik Lohmander and Karin Isaksson, my wonderful, lovely room-mates, always contributing with positive comments and help in every way.

Fuat Celebioglu, Lotta Anveden and Peter Emanuelsson, for your friendship and support.

All nurses at Bröstcentrum, Agneta Eriksson, Cecilia Arevald, Elisabeth Göransson, Marianne Unevik, Viveca Åberg and Karolina Fridblom, always so calm, professional and helpful.

All nurses at A23a, especially thanks to Jenny Larsson, Ann Eliasson, Marie Hamnstedt, Karolina Fridblom and Cassie Merenick for helping me with paper I.

All secretaries, especially Carina Ekberg, Chatrin Lindahl, Christel Nilsson and Birgitta Brännström, for keeping order in my world.

My present colleagues at the Department of Breast and Endocrine Surgery and former colleagues at the “Helicopter” for encouragement.

Patrick Hort for patience and invaluable linguistic revisions.

Henrik Olivecrona, my co-author and Stefan Jonson for helping me into the world of 3-D imaging.

To all my other dear friends, colleagues and family for support and help in different ways and for understanding my absence in the past year. But beware! My golf handicap is going to improve.

My family, Mum and Dad, my sister Evelyn and aunt Birgitt, for always being there for me.

My children, Max and Ariel, for truly helping me with my thesis in so many ways and for making me a very proud mother. To Urban, the love of my life, 25 years together, you are rock steady.

This thesis was supported by grants from BRO (Swedish Breast Cancer Association), Olle Engkvist Foundation, Percy Falk Foundation Swedish Cancer Society and ALF.